

ELECTROPHYSIOLOGICAL EVALUATION OF PATIENTS WITH POST-COVID ACUTE MOTOR NEUROPATHY

Thaier Kareem Abdul- Aa'ama, Sarah Ali Al kindy and Alkhansaa Sabah Ibrahim Harba

^{1,2,3} Al - Hussein teaching hospital, Karbala, Iraq

E-mail thaerkaromy970@gmail.com

ABSTRACT

Long-term "mechanical ventilation", which is frequently required for patients suffering from serious COVID-19, is predicted to cause major complications. Many of the survivors had ICUAW (intensive care unit-acquired weakness). However in the course of our post-COVID-19 follow-up, we discovered that in our clinic, we discovered that, in addition to the expected global weakness associated with muscle mass loss, a a sizable number of patients have a a sizable number of patients who have a a sizable number of patients who have a a sizable number of patients Multiple axonal mononeuropathies have caused debilitating localized neurological impairments in some of these patients. Among the many We have encountered 50 individuals with serious COVID-19 who have been released from our hospital's ICU. There were 16 percent of people with a "mononeuritis multiplex". In several instances, the "multi-focal character" of the flaw in these systems Patients were initially misdiagnosed because their symptoms were mistakenly attributed to "critical disease neuromyopathy." While "mononeuropathy" is well-known as a rare complication of critical care, our experience implies that it is extra frequent than that. In patients recovering from serious COVID-19, impairments are surprisingly common and often disabling

Keywords COVID-19, Neuropathy, Nerve injury, Mononeuritis"multiplex, Electrophysiological, post-infectious neurological syndromes (PINS)

How to cite :

Thaier Kareem Abdul- Aa'ama, Sarah Ali Al Kindy and Alkhansaa Sabah Ibrahim Harba. Electrophysiological Evaluation Of Patients With Post-Covid Acute Motor Neuropathy. *int j med sci*, 2022;2(2):41-55

INTRODUCTION

Coronaviruses (CoV) are a broad group of viruses that can end up causing everything from a regular cold to cancer. More lethal illnesses include "Middle East Respiratory Syndrome (MERS-CoV)" and "Extreme Acute Respiratory Syndrome (SARS-CoV)". A "new coronavirus (nCoV)" is another strain that hasn't been seen in people in a long time. Covids are zoonotic, which means they spread from one creature to another. SARS-CoV was delivered to individuals, according to definitive examinations. MERS-CoV was transmitted to people by "civet felines", whereas "MERS-CoV" was transmitted by dromedary camels. Many recognized COVID are circling in species that have not yet infected humans. Symptoms of the lungs, such as Heat, coughing, and breathlessness Breathing issues and shortness of breath are common indicators of illness. Diseases can develop to pneumonia, severe acute respiratory syndrome, kidney failure, and, in the worst-case scenario, death. Hand cleaning on a daily basis, the mouth and nostrils are covered when sneeze or coughing, and preparing meat and

poultry are all recommended. To prevent infection from spreading, it is normal practice to wash eggs thoroughly. Avoid personal interactions to anybody who is experiencing respiratory problems. such as coughing and wheezing. sneezing The nerve system has been harmed. Because of its "central nervous system (CNS)" consequences ("headache, dizziness, awareness disturbances, acute brain illness, seizures", etc.), COVID-19 infection causes neurological symptoms in the central nervous system (anosmia, ageusia, visual impairment, nerve pain), "peripheral nervous system (PNS)", and skeletal muscles. because of the "central nervous system's effects (CNS)". It can also result in encephalitis and a stroke. Since There has been an increase in the number of individuals infected with coronavirus sickness in December 2019. (COVID-19), "coronavirus 2" causes "severe acute respiratory symptoms (SARS-CoV-2)". The virus contains 79.5 % and 50percentage genes, respectively. "SARS-CoV" and "MERS-CoV" have sequence homology, respectively. The medical profession has been working overtime to combat the present pandemic. has had to overcome great obstacles. COVID-19 is among the most serious public health issues. among infectious respiratory infections. COVID-19 has been linked to a growing pattern of "central nervous system (CNS)" involvement. COVID-19 has also been linked to peripheral nervous system (PNS) symptoms, according to a growing body of research. The PNS symptoms related with COVID-19 review has been discussed

Pathophysiology of "COVID-19"

The virus infects humans by inhaling through the nose and then entering the nasal cavity. SARSCoV-2 binds to the nasal epithelium's ciliated secretory cells via ACE2. Due to the high viral load, viral reproduction occurs and the immunological response to the virus is limited. The "upper respiratory tract", "conducting airways", and "lower respiratory tract" all become affected. Viruses then infiltrate "type 2 pulmonary alveolar epithelial cells" and infect them via "ACE2". After a type 2 diabetes diagnosis, the immune system will respond in one of two ways. Alveolar epithelial cells in the lungs. The Cytokine response is the first form of immunological response. The release of "IL-1, IL-6, IL-8, IL-10, IL-12, TNF_, IFN_, and IFN_, CXCL-10, G-CSF, GMCSF, MCP-1, and MIP-1" causes neutrophils, CD4, and CD8 cells to be attracted, as well as "B cell differentiation". "Cytotoxicity" and lung damage are caused by all of these cells entering lung tissues. which can lead to "cytotoxicity and lung injury", which can lead to alveolar destruction in the end. ARDS is a disease that affects people ("Acute Respiratory Distress Syndrome"). Viral replication is the a 2nd sort of immune reaction. and the virus particles are released, which causes host cells to apoptose. With type 1 loss, the virus continues to grow and attack healthy alveolar epithelial cells. And"type two pneumocytes", which cause "ARDS" and alveolar damage, which can lead to respiratory failure and death. [6, 7]. The pathogenesis of The illness with "COVID-19" has been fully escribed.

Fig. 1 as follows:.

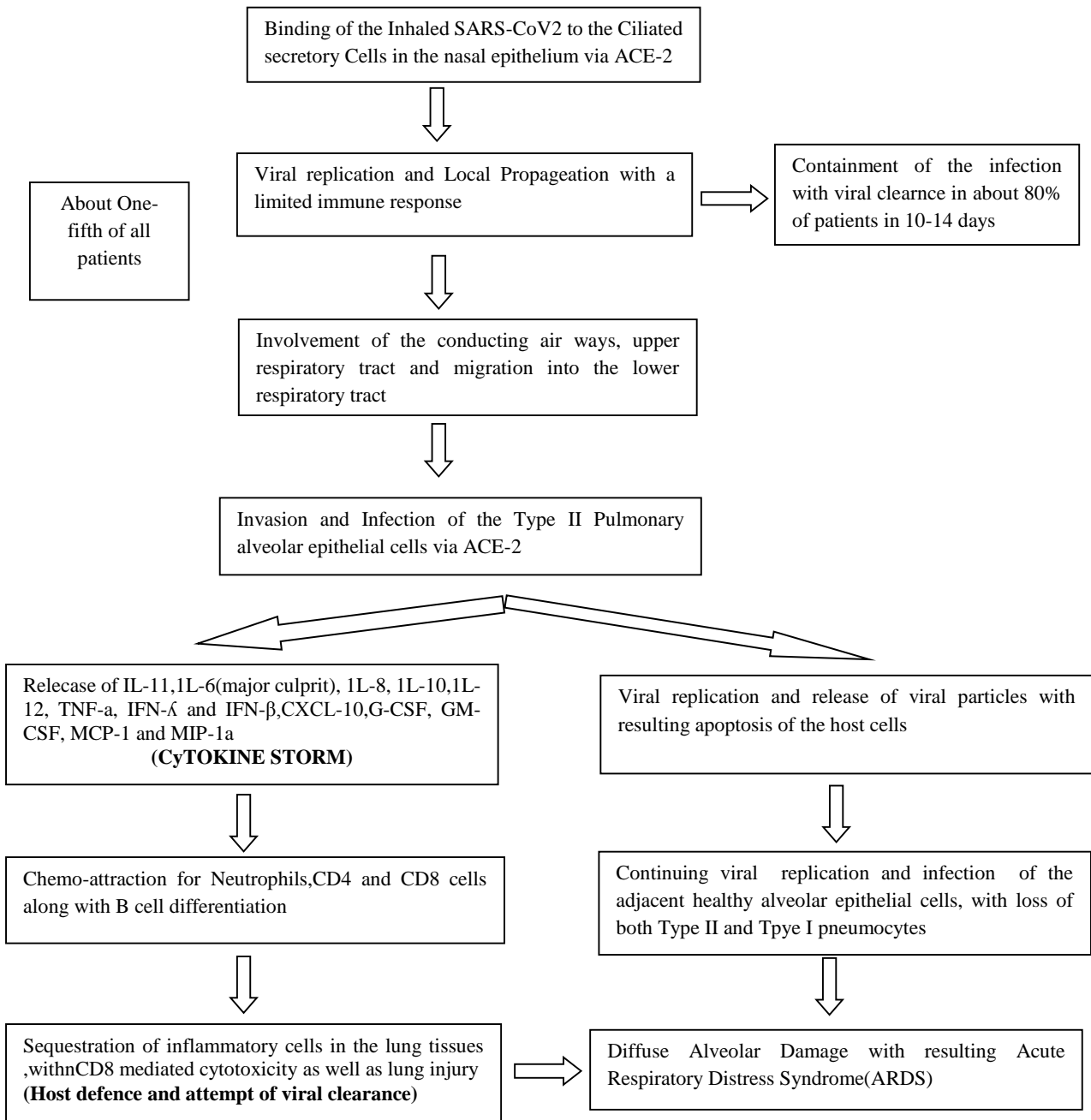
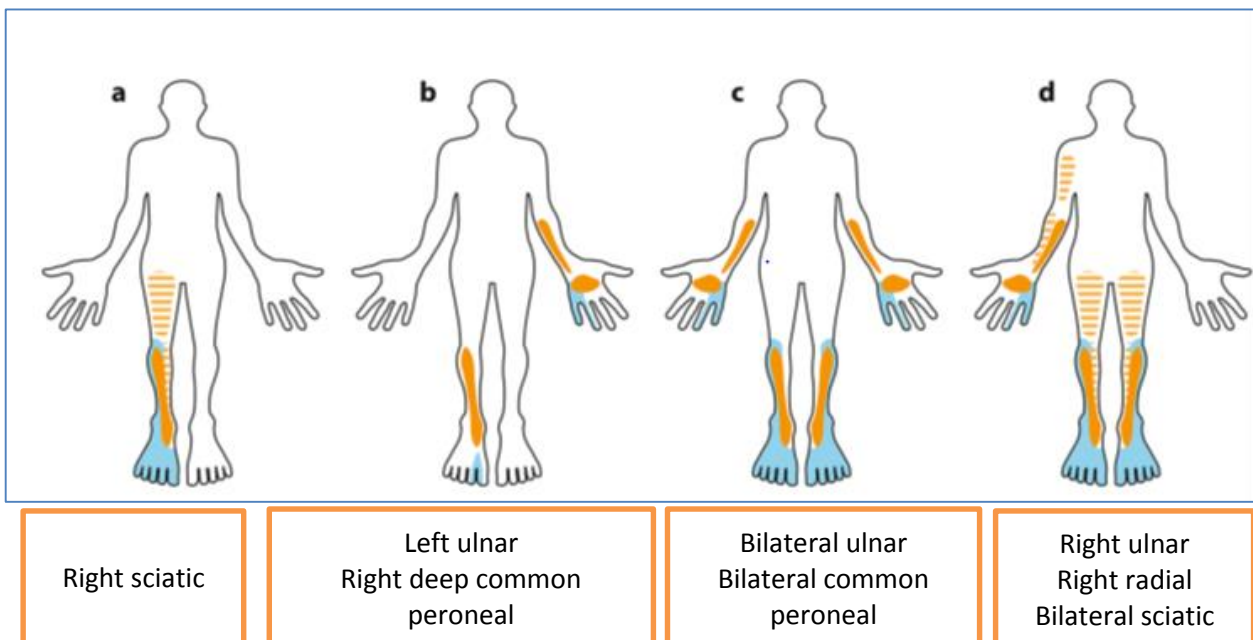
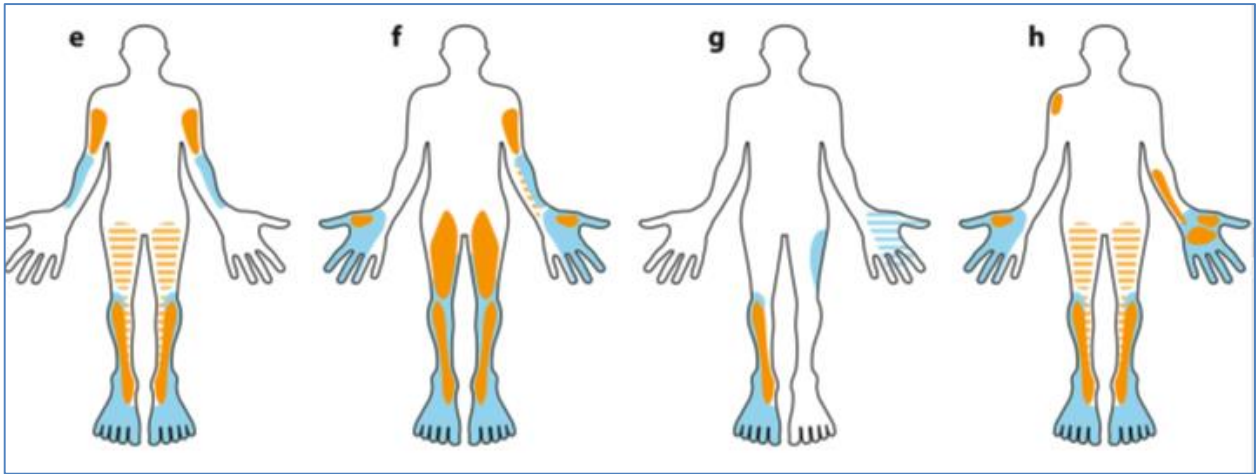


Fig. 1. "COVID-19" Pathophysiological mechanisms.
 "COVID-19" neuropathophysiology

"SARS-CoV-2" is a beta-coronavirus that belongs to the Coronaviridae family's Orthocoronavirinae subfamily and has a single-stranded RNA genome of 29,903 bases. "SARS-CoV-2" has a structure that is well-defined with Fourteen binding residues in total. "Glycoprotein spike (S)" SARS-CoV-2 has angiotensin-converting enzyme 2 (ACE2) receptors on its surface. Endocytosis of the virion is possible in a variety of host tissues. According to evidence, "SARS-CoV-2" neuro virulence may be linked to the quantity of ACE receptor activity in the nervous system. This receptor, however, is "Smooth muscle cells" in the "endothelium" express this protein. As a result, it is vital to look into its participation in the situation further. neurological complications etiopathogenesis Transmembrane

protease is involved in the internalization of "SARS-CoV-2". The S glycoprotein is trimmed and made easier to attach to by "serine 2 (TMPRSS2), furin, and cathepsins B and L (Cat B and L)". "SARS-CoV-2" cell entrance and ACE2. SARS-CoV-2 has showed neurotropism in varying degrees. The virus is thought to enter the neurological system through the "PNS terminals" of the olfactory nerve" and the "nasal nerve". SARS-CoV-2 may attach more strongly to the olfactory epithelium. Bilinska and colleagues claim that. [11], ACE2 and The sustentacular cells of the olfactory epithelium express TMPRSS2, implying that these units have a part in "SARS-CoV-2" viral entrance and olfactory impairment. The Entrance protein activity, in particular, is elevated in animals that are elderly, which could explain why SARS-CoV-2 infection is more common in older people [11]. Lately, a possible trans synaptic pathway from the nasal respiratory epithelium to the brain via the trigeminal nerve branch has been hypothesized., though this has yet to be confirmed. [12] Verification is required. A A retrograde spread through endocytosis or exocytosis via trans synaptic transfer, as well as a fast axonal transport technique of vesicle transport conveying the virus along microtubules back to neuronal cells, were also postulated. [13] Cell bodies in the CNS of COVID-19 individuals, viral RNA was found. was discovered during autopsies [14, 15]. "SARS-CoV-2" causes downregulation in the "neurological system". ACE2 inhibits the alternative pathway of the "renin-angiotensin system (RAS)" "(ACE2-Ang-(1-7)-Mas)". Such The conventional RAS pathway is therefore over activated as a result of the under activation "(ACE-Ang II-AT1R)". Oxidative stress, neuro inflammation, vasodilation, and thrombosis are all possible outcomes. events. The cerebral cortex was affected in an unequal manner in animal models, with vertical formations with infected cells. Except for the cerebellum, most brain regions have a a large number of infectious cells, including patches and sensory regions. SARS-CoV-2 has the ability to disrupt vascular architecture in the cortex [16]. The virus is thought to disrupt the brainstem's respiratory centers.



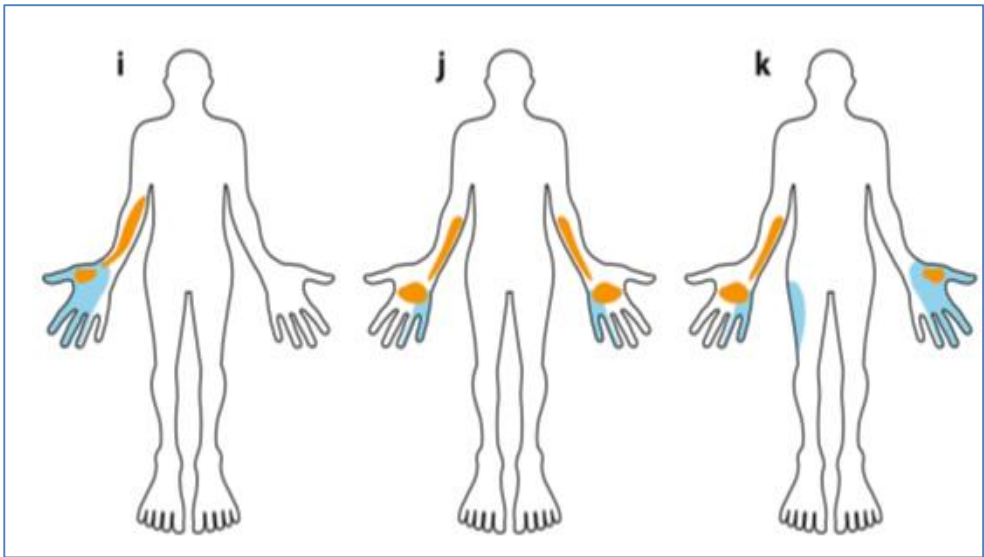


Bilateral
msculocutaneous
Bilateral sciatic

Bilateral median
Left msculocutaneous
Left posterior
interosseous
Bilateral femoral
Bilateral sciatic

Left superficial
radial
Right common
peroneal
Left
lateralcutaneous
Nerve of thigh


Left ulnar
Bilateral median
Right axillary
Bilateral sciatic



key



Motor
deficit



Sensory
deficit

Right median
Right anterior
interosseos

Bilateral ulnar

Bilateral ulnar
Left median / Right lateral
Cutaneous nerve of thigh

fig. 2 Patients recovering from severe COVID-19 show a schematic homuncular representation of sensory and motor impairments. Posterior muscle groups are indicated by hatched shading (hamstrings and triceps).

COVID-19 PNS Manifestations COVID-19

can influence the PNS even before the pneumonia clears up, if it meets the diagnostic criteria for acute pneumonia. Polyradiculoneuropathy is a kind of polyradiculoneuropathy [13]. Stuart-Neto et al. [19] examined the medical data of 89 COVID-19 patients. Peripheral neuropathy was observed in 6.7 percent individuals with COVID-19 who have serious respiratory difficulties, according to the investigators. The involvement of the PNS could be due to SARS-dysregulation CoV-2's of the systemic immune response. Hyperinflammation throughout the body In COVID-19 individuals, "macrophage activation syndrome," also known as "secondary hemophagocytic lymphohistiocytosis", has been suggested [20]. These immune-mediated signs and symptoms Typically, this happens after the infection's acute phase has passed.

"Myalgias", "Nerve Pain", and "Skeletal Muscle Nerve discomfort" was identified in (4.5 percent) and (0.8 percent) of the individuals with serious and non-serious injuries, respectively. "COVID-19", respectively. "Skeletal muscle injury" was detected in 19.3% and 4.8 percent of individuals with serious and non-serious pain, respectively. "COVID-19", to be precise. It's vital to remember that elevated creatine kinase (CK) levels aren't the lone indicator of disease. Muscle injuries are not always specific. and, in extreme cases, may be linked to extended bed rest and medications. "COVID-19" has resulting in greater than a direct muscle injury in some circumstances. "Myopathy and myalgia" were found in (3.1)percent and (17.2)percent of COVID-19 patients, respectively, in the ALBACOVID registry. In other investigations, myalgias were found in 15.79 percent to 100 percent of COVID-positive individuals. Disorders of the "Neuromuscular Junction New-onset myasthenia gravis (MG)" can also arise following COVID-19 infection, and this, like other neurological symptoms, could be due to molecular mimicry processes. Following the documentation of 3 scenarios of "new-onset acetylcholine receptor antibody-positive (antiAChR+) MG" after "COVID-19", Restivo et al. [19] recommended this. Indeed, research suggests that COVID-19 can cause autoimmunity by enhancing "T cell signaling" [19]. "Acute respiratory distress syndrome (ARDS)" in "COVID-19", as well as "respiratory muscle failure" in MG crises, may imply a poor prognosis

Differential Diagnosis of Peripheral Nerve Injury in patients with COVID-19				
Etiology	Recommended Imaging	MRI Characteristics	US Characteristics	Pertinent Clinical Features
Inflammatory neuropathy (21,26)	MRI,US	Diffuse signal hyperintensity of cauda equina/nerve roots/plexus, often asymmetric; nerve enhancement if acute	Thickening of the affected nerve	Progressive weakness, following infection (acute and chronic forms)
Parsonage-Turner syndrome (17,21,34)*	MRI(for better evaluation of muscle),	Signal hyperintensity, thickening, often of	Hypoechoogenicity, thickening of affected nerve (ie, suprascapular, long thoracic nerve)	Sudden and rapid onset, following infection

	US(for small nerves not well seen at MRI)	multiple Plexus nerves; muscle edemalike signal		
Positioning-related Peripheral nerve injury of extremities (11,16,17)	MRI(for better evaluation of muscle), US (for dynamic imaging, well tolerated)	Signal hyperintensity, of affected nerve with or without muscle edemalike signal if acute, fatty atrophy if chronic	Hypoechogenicity, thickening of affected nerve; with or without subluxation on dynamic maneuvers; with or without muscle atrophy, hyperechogenicity if chronic	Weakness/sensory deficit acquired during hospital course; often asymmetric; use of prone positioning
Positioning-related brachial plexus injury(11,16,17)	MRI , US (limited by clavicle)	Signal hyperintensity, thickening of upper or lower plexus with or without muscle edemalike signal if acute, fatty atrophy if chronic	Hypoechogenicity, thickening of upper or lower plexus with or without muscle atrophy, hyperechogenicity if chronic	Weakness/sensory deficit acquired during hospital course; often asymmetric; use of prone positioning
Distal symmetric Polyneuropathy(17)	Typically not performed for diagnostic purposes	Diffuse signal hyperintensity of nerves with or without multifocal muscle edemalike signal/ fatty atrophy based on etiology and chronicity	Thickening of the affected nerve with or without multifocal muscle atrophy if chronic	Preexisting Polyneuropathy plus comorbidity (ie, diabetes) versus acquired polyneuropathy and myopathy in critical illness
Nerve entrapment (16-18)	MRI or US	Signal hyperintensity of affected nerve, nerve compression, or altered	Hypoechogenicity, thickening of affected nerve, nerve compression or altered course due to mass	Weakness/sensory deficit acquired while undergoing with or without

		course due to mass effect with or without adjacent hematoma	effect with or without adjacent hematoma	swelling/ palpable mass
<p>Note.-COVID-19= coronavirus disease 2019.</p> <p>*The diagnosis of Parsonage – Turner Syndrome is one of exclusion and the rarity thus far of reported immune-mediated cases after COVID-19 (aside from Guillain- Barre' and its variants) should be considered. Source.- Reference 8.</p>				

METHODS AND MATERIALS

This is an investigative research of 50 individuals who developed PINS after COVID-19 and were admitted to the Al-Hussein teaching hospital in Karbala, Iraq, in March 2020. Throughout the 1st "COVID-19" epidemic, During During the same time period (March 2020), 115 people were diagnosed with Other individuals with "neurological problems" were submitted to the hospital's emergency department (ed. Our "Neurology Unit", as well as other neurological divisions, hospital. There were no other individuals with "myelitis" among them. noted, and yet another unrelated individual. A person infected with SARS-CoV-2 was admitted to the hospital. The entire diagnostic and therapeutic process was completed in accordance with clinical demands, as well as independently by the research objectives COVID-19 infection was verified in all subjects. a "nasopharyngeal swab", followed by "serum IgG detection ."There was no prior history of "SARS-CoV-2 antibodies" in any of the individuals. neurological illness, either "central or peripheral, cranial or spinal Surgery", as well as a "catastrophic head or spinal damage" CSF (The "cerebrospinal fluid" was gathered and analyzed. routine analyses, such as "white blood cell count" and "level of protein and glucose analysis", as well as "real-time quantitative PCR (RT-qPCR)" " Chest radiography" and, in certain cases, MRI are used to screen for SARS-CoV-2. Scanners were also used at the start of the study. Following the completion of the examination for diagnosis and acute care, In the ICU, "neurological therapies" are administered (ICU), All patients were subjected to a thorough clinical assessment using the "Medical Research Council's (MRC's)" Muscle Strength Assessment Scale, Measure of Functional Independence. At baseline, the "FIM scale", the "Barthel index", the "Tinetti and Hauser scale", and the "Tinetti and Hauser scale" were all used. as well as at visits to update An comprehensive "neurophysiological examination" At the baseline, 3-, and 6-month intervals, an investigation was also carried out. except in the case of individual #3, who had a 6-month follow-up Only after three months was an electrophysiological reevaluation performed. after the development of neurological symptoms Nerve testing was part of the electrophysiological evaluation. conduction and electromyography (EMG) investigations, in addition to Evaluating motor evoked potentials (MEPs). Every investigation were carried out using a "five-channel electromyography" (Synergy, Medelec, United Kingdom) The preceding is a description of motor nerve conduction. The four limbs' parameters were assessed as shown inThe amplitude of the compound muscular action potential conduction velocity of the common peroneal muscle, as well as its proximal delay. The ulnar, tibial, and femoral nerves, as well as the tibial and ulnar F wave latency nerves. metrics of "antidromic sensory nerve" conduction of "The limbs" were made up of the magnitude of "sensory nerve action". Sural and ulnar nerve potentials and conduction "velocity EMG" of the "tibialis anterior", "gastrocnemius medialis", and "vastus intermedius ."The lateralis, "first dorsal interosseous, and

deltoid muscles" were all tested. carried out bilaterally using "concentric needle electrode". The existence of the following "EMG parameters" was evaluated: Fibrillation potentials and positive sharp spikes are examples of spontaneous activity. motor (waves and complicated repeated discharges), action as a group analysis of potential ("MUAP") (i.e., time as well as amplitude), and MUAP" spatial recruitment" (normal, decreased, or early) pattern of interference) MEPs were acquired using a STM9000, "single-pulse monophasic electromagnetic stimulator Ates Medica Device, EB Neuro, Italy") that is capable of producing a A maximum output of 2.4 Tesla is possible. Hotspots in the cortical and spinal cord The muscles abductor hallucis and abductor digiti minimi were tested. a 90-mm circular coil was used to stimulate (inner diameter of 5 cm). The intensity of a magnetic pulse, represented as a percentage of the The MEP was obtained with the maximum stimulator output. Size of suprathreshold amplitude. "The MEP parameters" listed below "Cortical and peripheral MEP amplitudes", as well as cortical as well as "peripheral motor conduction time" and "central motor conduction time conduction time (CMCT)", which is described as the distinction between The time it takes for cortical and peripheral motor transmission to occur..

RESULTS

Table 1 Electrophysiological categorization at its most fundamental level

	"ANAC-19 * "	"NCN #"
Definite	(30.77)	(37.50)
Probable	(69.23)	(62.50)
Demyelinating	(84.62)	(50)
Axonal	(15.38)	(37.50)
Equivocal	(0)	(12.5)

_ "Acute neuropathy associated with Covid-19"

"Non-Covid neuropathy"

Table 2 Nerve Conduction Study on Day 14 Following the Onset of Neurological Symptoms

"Motor Nerve"	"Side"	"Distal latency (ms)"	"Amplitude (mV)"	Velocity (m/s)"	"F-wave frequency (%)"
Median	Right	4.8	2.5 / 2.1	48.1	68.8
Ulnar	Right	3.3	7.9 / 7.1	61.1	Not tested
Peroneal	Right	11.1	1.8 / 1.2	41.4	Not tested
Peroneal	Left	8.1	2.3 / 1.4	34.2	Not tested
Tibial	Right	5.2	3.4 / 3.1	53.3	0
Tibial	Left	3.6	5.1 / 3.9	42.5	0

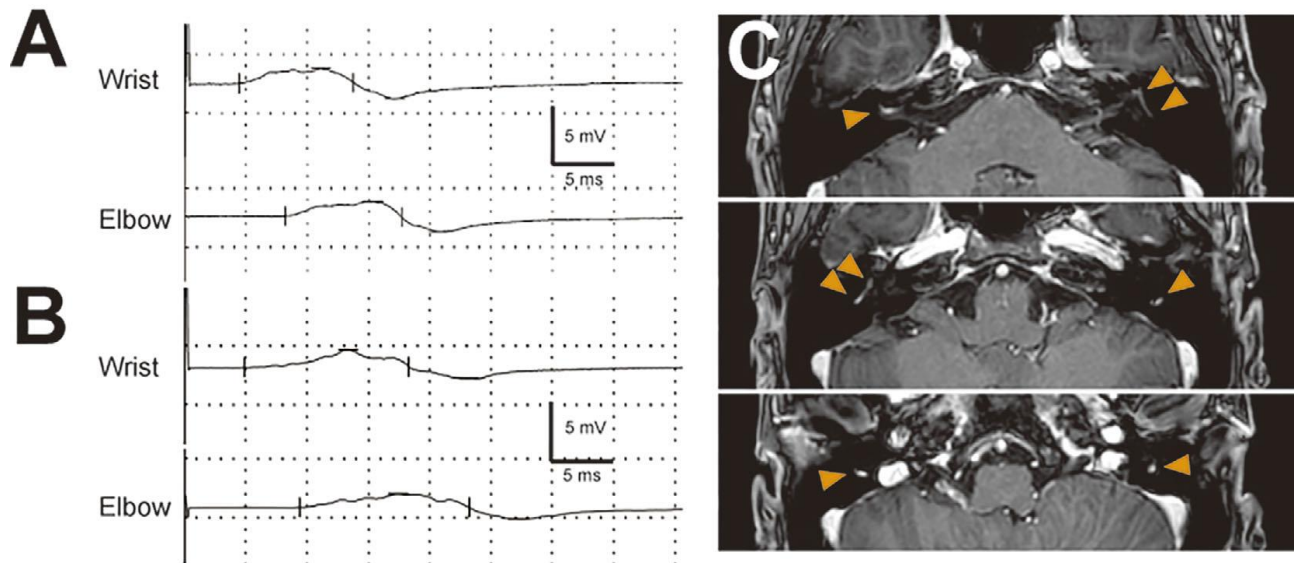


Figure 2. A, B: Right median motor nerve conduction study on days 8 (A) and 14 (B) after the onset. The upper and lower parts show wrist and elbow stimulation, respectively. "The amplitudes of the compound muscle action potentials" are decreased to 2.6 mV (A) and 2.5 mV (B), respectively, from peak to peak. Abnormal temporal dispersion was observed on day 8 (A) and was more prominent on day 14 than at other points (B). C: "Contrast-enhanced T1-weighted magnetic resonance imaging of the head" on day 25.

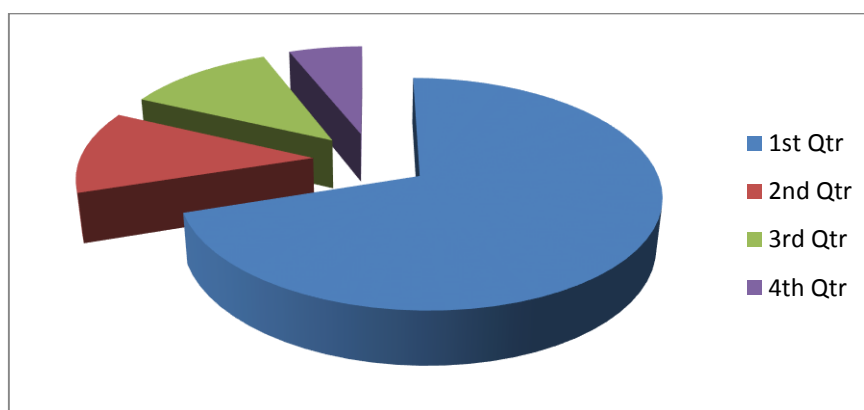
Table 3 Data on Covid-19-related neuropathy are compared.

	Uncini et al., 2021	Frithof et al., 2021	Current study
Covid cases	24	14	13
Controls	48	10	8
Mean age of cases (years)	NA	60.5 ± 11	65.54 ± 8.6
Neuropathy type	AIDP	CIN	ANAC 19
Axonal cases	0/24	7/14	2/13
Demyelinating cases	24/24	NA	11/13
Diabetic cases	3	NA	11

Table 4. Electrophysiological findings showing motor neuropathy of fifty patients

Motor nerve conduction studies						
Nerve	CMAP Onset, μ (ms)	CMAP Duration, ms	Amplitude, mV	Distance, mm	CV, M/s	F-M lat, ms
Fibular – peroneal motor left						
Ankle-EDB	4.45	6.3	8.1			62.8
Ab.Knee-BL.knee	14.9	11.5	2.8	80.0	36.4	
Bl.knee-ankle	12.7	10.3	2.9	320	38.8	
Fibular – peroneal r motor right						
Ankle-EDB	6.36	13.2	4.6			
Bl.knee-ankle	14.7	15.1	1.29	330	39.6	
Ab.knee-BL.knee	17.4	12.2	1.25	70.0	25.9	
Median motor LT						
Wrist-APB	3.47	12.1	6.3			31.1
Elbow-wrist	8.31	10.6	5.4	225	46.5	

Axilla-elbow	12.4	12.8	6.1			
Erb's axilla	13.6	13.4	3.7			
Median motor RT						
Wrist-APB	4.38	8.5	8.2			
Elbow-wrist	9.83	8.5	6.0			
Axilla-elbow	12.9	10.6	4.4			
Erb's axilla	17.2	13.2	3.8			
Peroneal-TA motor LT						
Be.Fibrular head	2.76	18.7	3.7			
Lat.Popliteal fossa Be. Fibrular head	4.85	17.4	3.2	70.0	33.5	
Peroneal-TA motor RT						
Be.Fibrular head	2.71	15.5	3.1			
Lat.Popliteal fossa Be. Fibrular head	4.54	15.4	3.2	70.0	33.5	
Post-tibial motor left						
Med.ankle- abd.hal	4.14	14.9	9.3			71.9
Pop.fosso-med.ankle	14.9	15.2	2.0	390	36.2	
Post-tibial motor right						
Med.ankle- abd.hal	5.57	12.9	8.5			73.9
Pop.fosso-med.ankle	16.1	12.9	1.90	390	37.0	
Ulnar motor RT						
Wrist- ADM	2.30	9.7	9.2			36.1
BL.elbow-wrist	7.16	8.8	5.6	230	47.3	
Ab.elbow-wrist						
Ab.elbow-BL.elbow	9.34	8.8	4.8	100	45.9	
Axilla- Ab.elbow	12.8	9.2	3.1			
Erb's axilla	15.4	63.5	1.75			



1st Qtr	70%	Acute inflammatory demyelinating polyneuropathy (AIDP)
2nd Qtr	12%	Acute motor and sensory axonal neuropathy (AMSAN)
3rd Qtr	12%	Miller-Fisher syndrome (MFS)
4th Qtr	6%	Acute motor neuropathy (AMN)

Figure.3 Electrophysiological post-covid acute motor neuropathy

DISCUSSION

Peripheral nerve system participation in COVID-19 patients is becoming more prevalent. An early Chinese research found [8], it was anticipated that 8.9 percent of individuals were affected; nevertheless, It is more likely underreported, necessitating additional electrophysiological testing. investigations to ascertain its prevalence and properties in reality. This participation could be the outcome of direct interaction. "neuro-invasion" or an "autoimmune", "post-infectious" condition Recognizing the sequence and mechanism [8]. of events that result in neurological injury in patients with "COVID-19" could aid in early detection and therapy. and The importance of pattern research in the future is emphasized. Interaction of the peripheral and central nervous systems in "COVID-19" individuals [9]. A rare type of peripheral neuropathy is neuralgic amyotrophy. It has only been observed infrequently in connection with COVID-19, as far as we know. A PubMed search was performed. carried out using the following keyword combinations: "SARS-CoV-2", "COVID-19", and neuralgic amyotrophy Brachial plexopathy is a condition that affects the nerves in the arms and hands It uncovered only three case reports in until the time of writing, the literature [5–7] Cacciavillani et al study's includes a "Pure sensory neuralgic amyotrophy" individual as a result of lacking any clinical significance, connected to "SARS-CoV-2 infection" or electrophysiological manifestations of motor nerve involvement A patient was mentioned in Siepmann et al report. .s as an uncommon clinical condition involving only the median nerve Neuralgic amyotrophy manifests itself. A third report from Mitry and his colleagues team found a "T2-weighted signal" that was hyperintense. "supraspinatus", "infraspinatus", "teres minor, teres major, teres minor, teres major, teres minor, teres major, teres minor, teres major", and "trapezius muscles" on MRI, on steroids, there was an initial benefit. orally These various post-production presentations The various causes of "COVID-19 neuralgic amyotrophy" are highlighted. Symptom variability in people with "peripheral neuropathy Involvement" of the neurological system in "SARS-CoV-2 infection", as well as the significance of a comprehensive assessment of patients with COVID-19 is used to treat neurological impairments [9]. "Neuralgic amyotrophy" is an unique condition that is affects mostly females. prevalent in males, It is characterized by severe neuropathic pain and mostly damages the roots of the brachial plexus. In C5, "Multifocal paresis and sensory loss" accompany the discomfort. C6 distribution, and less frequently in C7 distribution. It is divided into two subtypes, HNA ("hereditary neuralgic amyotrophy") and "idiopathic neuralgic amyotrophy amyotrophy (INA)", and it is believed that 2–3 cases/year are affected. 100,000 people per year The involvement is mostly one-sided. about 70% of instances, and bilateral or asymmetric in the remaining thirty percent Electrophysiological investigations confirm the diagnosis. and, on occasion, indications of strain in the supra and MRI images of the infraspinatus muscles [10, 11]. The disease's genesis is not well understood; nonetheless, a response mediated by the immune system that is caused by The cause is thought to be an earlier or concurrent infection. 43 percent of the time [12]. Some aspects of our report are unique. in compared to the other occurrences that have been documented First, consider the "bilaterality". characterized by distress and exhaustion, which is an unusual trait of In and of itself, neuralgic amyotrophy. Second, the start of COVID-related symptoms at an exceptionally early stage during the initial presentation 19, implying that a direct viral neuroinvasion is more likely. rather than an "autoimmune post-infectious reaction" to [13] "SARS-CoV-2". Furthermore, our findings revealed "hyperintense T2 weighted signal" from the supraspinatus and "infraspinatus muscles" in an MRI Skeletal denervation explains this. muscles in the brachial plexus nerve distribution, as a result of intramuscular edema [14]. MRI aids in decision-making. Other causes of painful shoulder weakness

should be considered. There is no established treatment for “neuralgic amyotrophy”.. if there are no randomized controlled trials (RCTs). An acceptable Adults were observed to benefit with For one week, patients were given oral prednisone (1 mg/kg per day), followed by a 10-mg-per-day taper day the following week. [15] IgG ("intravenous immunoglobulin") (In addition, intravenous immunoglobulin (IVIg) has been proposed as a treatment alternative. [16]. of steroid contraindications or the appearance of adverse effects, similar to our situation This sequence of instances emphasizes a key neurological concept. issue that usually occurs in people with severe COVID-19, which has a negative impact on long-term results and has a significant impact on their recovery requirements. Given that, in a considerable proportion, this difficulty is visible of the individuals who have been released from a hospital's ICU solitary hospital (16 percent of the individuals in our treatment group) and The cost of recovery on a global scale could be enormous.. Furthermore, Given ICUAW's high expectations, these focal points Inadequate performance may go overlooked. The fundamental cause of these "neuropathies" is unknown. to be determined Patient-related handling and positioning of mechanical factors are recognized to occur on occasion produce localized neuropathy [7], Individuals with severe COVID-19 are substantially more likely to suffer from nerve injury, raising the possibility of such damage. Against this, we observed There was no sign of the typical demyelinating symptoms. Many of our patients have neuropathies as a result of such traumas. in locations where compression would be quite unlikely or traction ("including musculocutaneous, proximal, and distal") "Sciatic neuropathies (middle and high levels)". From both a clinical and an electrophysiological standpoint, There are a number of similarities between the impairments we've discovered in our individuals involves "vasculitic neuropathies" such as "lumbosacral vasculopathy Neuropathy" of the radiculoplexus ("Bruns–Garland syndrome") and paralysis ("Parsonage–Turner syndrome") [8]. However, These syndromes are frequently, but not always, followed by severe pain, which was not a common occurrence characteristic in our sample. However, Because our individuals' inadequacies grew while they were drugged and ventilated, this stage of the illness had to be concealed.

CONCLUSION

Our article adds to the accumulating growing body of proof that In COVID-19 individuals, the peripheral nervous system is involved. Despite its rarity, neuralgic amyotrophy should be taken seriously. COVID-19 patients with presenting symptoms were suspected and ruled out. with severe shoulder and arm muscular pain and weakness This study emphasizes the significance of thorough evaluation. of COVID-19 individuals with neurological impairments, to Avoiding diagnostic delays and allowing for early intervention The 2019 worldwide coronavirus pandemic (COVID-) (19) has posed a number of challenges to the health-care system. There are still unanswered concerns about our comprehension of the the virus, its aftereffects, and the long-term impacts. Damage to the Peripheral Nerve Mechanisms in COVID-19 individuals is possible. multifaceted, including systemic illness complications Direct neuroinvasion as well as an immunological reaction additional investigation is required to understand the pathophysiologic mechanisms Regarding peripheral nerve damage in "COVID-19" patients, including the potential of "acute respiratory distress syndrome". The infection of coronavirus 2 as a "novel neuropathogen" and its link with "prone positioning" in the "COVID-19" setting– Adult respiratory distress syndrome is related. In the same vein, More studies need to be conducted to see if COVID-19 individuals have a higher risk of peripheral nerve injury. which could be fatal. because to comorbidities like "diabetes, obesity," and advanced age, or,

very probably, a virus-induced condition of hyper inflammation. "MR neurography" and "high-resolution US" are both great. methods for diagnosing "peripheral nerve damage" that can be modified suit the needs of persons and their possible constraints Using "COVID-19", There were 19 test findings, taking into account their most recent COVID 19 There were a total of 19 testing findings. Because practice guidelines are subject to alter, "Radiologists" It is necessary to stay updated with existing investigation. recommendations. Radiologists with the requisite expertise can provide light on the etiology of peripheral nerve injury in COVID-19 patients, which could have a direct impact on the patient's condition. Treatment and management decisions COVID 19-infected patients Imaging was performed on 19 survivors and survivors with "neuromuscular problems". The study of "peripheral nerves" can help doctors make decisions. Rehabilitation services, as well as patient and family therapy, are available.

REFERENCES

1. Abu-Rumeileh S, Abdelhak A, Foschi M, Tuman H, Otto M. Guillain-Barrésyndrome spectrum associated with COVID-19: an up-to-date systematic review of 73 cases. *J Neurol* 2021;268(4):1133–70 AprEpub 2020 Aug 25. PMID: 32840686; PMCID: PMC7445716. doi: 10.1007/s00415-020-10124-x .
2. Akbar DH , SA Mira , Zawawi TH , Malibary HM . Subclinical diabetic neuropathy: a common complication in Saudi diabetics. *Saudi Med J* 2000;21(5):433–7 MayP- MID: 11500676
3. Asbury AK, Cornblath DR. Assessment of current diagnostic criteria for Guillain-Barrésyndrome. *Ann Neurol* 1990;27 Suppl:S21-4.PMID: 2194422. doi: 10.1002/ana.410270707 .
4. Bansal V, Kalita J, Misra UK. Diabetic neuropathy. *Postgrad Med J* 2006;82(964):95–100 FebPMID: 16461471; PMCID: PMC2596705. doi: 10.1136/pgmj.2005.036137 .
5. Broderick JP, Adeoye O, Elm J. Evolution of the Modified Rankin Scale and Its Use in Future Stroke Trials. *Stroke* 2017;48(7):2007–12 JulEpub 2017 Jun 16. PMID: 28626052; PMCID: PMC5552200. doi: 10.1161/STROKEAHA.117.017866.
6. Spectrum of Acute Neuropathy Associated With Covid-19: A Clinical and Electrophysiological Study of 13 Patients From a Single Center Sai Deepak Yaranagula *, VenkataKrishnaChaitanya Koduri
7. *Consultant Neurologists, Department of Neurology, AIG hospitals, Hyderabad, Telangana, India*, International Journal of Infectious Diseases journal homepage: www.elsevier.com/locate/ijid
8. Peripheral Nervous System Manifestations Associated with COVID-19 Sasan Andalib1 & José Biller2 & Mario Di Napoli3, <https://doi.org/10.1007/s11910-021-01102-5>
9. Imaging Review of Peripheral Nerve Injuries in Patients with COVID-19 Article Type: Review, Claire E. Fernandez1 Colin K. Franz MD/PhD2,3,4 Jason H. Ko MD, MBA5
10. McWilliam, M., Samuel, M., & Alkufri, F. H. (2021). Neuropathic pain post-COVID-19: a case report. *BMJ Case Reports CP*, 14(7), e243459.
11. Neuralgic amyotrophy associated with COVID-19 infection: a case report and review of the literature Ismail Ibrahim Ismail1 & Ehab A. Abdelnabi2 & Jasem Y. Al-Hashel1,3 & Raed Alroughani4 & Samar Farouk Ahmed1,5 Received: 31 January 2021 /Accepted: 16 March 2021 # Fondazione Società Italiana di Neurologia 2021
12. Sawcer, S., & Newcombe, V. (2020). Mononeuritis multiplex: an unexpectedly frequent feature of severe COVID-19.

13. Review article on COVID-19 and Guillain-Barré syndrome U. Juhi Patnaik1,* 1*Jawaharlal Nehru Medical College, Datta Meghe Institute of Medical Sciences, 442001 Sawangi Meghe, Wardha*
14. Clinical and Electrophysiological Outcome Measures of Patients With Post-Infectious Neurological Syndromes Related to COVID-19 Treated With Intensive Neurorehabilitation Micol Avenali 1,2†, Daniele Martinelli 1,2†, Massimiliano Todisco1,3
15. Zhao H, Shen D, Zhou H, Liu J, Chen S. Guillain-Barré syndrome associated with SARS-CoV-2 infection: causality or coincidence? *Lancet Neurol.* (2020) 19:383–4. doi: 10.1016/S1474-4422(20)30109-5
16. Toscano G, Palmerini F, Ravaglia S, Ruiz L, Invernizzi P, Cuzzoni MG, et al. Guillain–Barré Syndrome Associated with SARS-CoV-2. *N Engl JMed.* (2020) 382:2574–6. doi: 10.1056/NEJMc2009191
17. Zito A, Alfonsi E, Franciotta D, Todisco M, Gastaldi M, Cotta Ramusino M, et al. COVID-19 and Guillain–Barré syndrome: a case report and review of literature. *Front Neurol.* (2020) 11:909. doi: 10.3389/fneur.2020.00909
18. Asadi-Pooya AA, Simani L. Central nervous system manifestations of COVID-19: A systematic review. *J Neurol Sci.* (2020) 413:116832. doi: 10.1016/j.jns.2020.116832
19. Keyhanian K, Umeton RP, Mohit B, Davoudi V, Hajjighasemi F, Ghasemi M. SARS-CoV-2 and nervous system: from pathogenesis to clinical manifestation. *J Neuroimmunol.* (2021) 350:577436. doi: 10.1016/j.jneuroim.2020.577436
20. Munz M, Wessendorf S, Koretsis G, Tewald F, Baegi R, Krämer S, et al. Acute transverse myelitis after COVID-19 pneumonia. *J Neurol.* (2020) 267:2196–7. doi: 10.1007/s00415-020-09934-w
21. Imaging Review of Peripheral Nerve Injuries in Patients with COVID-19 *Claire E. Fernandez, BS • Colin K. Franz, MD, PhD.*
22. Guillain-Barre Syndrome following COVID-19 Infection: First Case Report from Kuwait and Review of the Literature Walaa A. Kamel a, b Ismail Ibrahim Ismail a Jasem Yousef Al-Hashel
23. Cranial Nerve Involvement and Dysautonomia in Post- COVID-19 Guillain-Barre Syndrome Toshiyuki Kakumoto1, Satoshi Kobayashi 1, Hayato Yuuki . Prevalence, clinical characteristics and outcomes of Guillain–Barré syndrome spectrum associated with COVID-19: A systematic review and meta-analysis Lina Palaiodimou1 | Maria-Ioanna Stefanou1